-4498

DETERIORATION IN LEATHER QUALITY DUE TO SHEEP DERMATITIS.

S. NEDUNCHELLIYAN, M. SUGUMAR & S. C. NANDY

Central Leather Research Institute, Madras.

Received on March 27, 1979.

Leather making potentiality of sheep skins is greatly affected by dermatitis, an animal disease caused by virus. Dermatitis lesions in raw sheep skin appear on the hair side as circular, raised mushroom shaped nodules and rubbery in consistency and on the flesh side as slightly depressed circular spots. A number of developing lesions are exposed only after unhairing. Finished leathers are found to be severely damaged due to the presence of the raised nodules having tunnel like depressions around them and grain damage caused by the removal of the scabs during mechanical operations. The influence of dermatitis on the histopathological characteristics of raw skin and on the physical properties of tanned leathers has been studied.

Several diseases characterised by cutaneous lesions among sheep and goat have been reported[1,2,3,4] in India and elsewhere which exhibit striking similarities in their clinical manifestation and gross pathology. These include pox, dermatitis and contagious pustular dermatitis in sheep and goat. All the above diseases are known to be caused by viruses.

An acute, highly fatal disease of goat characterised by specific skin eruptions was reported by Haddow and Idnani.[2] Detailed study of the lesions and immunological tests revealed this to be different from pox disease. Green[3] made a survey of skin diseases of goat in Kenya and described a similar disease as 'nodular dermatitis', having more or less identical gross and microscopical appearance.

Katiyar[5] described an acute (or sub-acute) disease of sheep by a filterable virus which was present both in the blood and in skin lesions during the course of illness. The skin lesions started with erythema all over the body surface and then developed into numerous raised circumscribed nodules of rubbery consistency even in the parts densely covered with wool. One remarkable characteristic feature of such nodules was that they never developed into vesicles and pustles. He concluded this to be a slight variance from that of classical sheep pox and observed that the virus causing sheep dermatitis was different from those responsible for goat dermatitis and contagious pustular dermatitis. This disease was also reported in different parts of India and was referred to as 'sheep dermatitis'. The incidence of 'nodular dermatitis' in sheep was also recorded by Green.[4]

Green studied the influence of nodular dermatitis in goat on leather quality but the effect of sheep dermatitis on leather quality has not been reported so far. As the causa-

tive viruses for sheep and goat dermatitis were reported[5] to be different, it was decided to study the type and extent of damage caused by sheep dermatitis on leather.

Materials and methods

Fresh sheep skin samples with dermatitis lesions in the centre were cut out, fixed in 10% formalin, embedded in paraffin and 5 μ sections were cut. Sections were stained by Haematoxylin and Eosin method, mounted on slides and studied under the microscope.

Hydrothermal stability of collagen fibres from dermatitis affected and unaffected areas of sheep skin was determined using a micro-shrinkage meter and the values are expressed in °C.

Red hairy sheep skins affected by dermatitis were collected from the slaughter house and then cured by salting. Wet salted skins were taken in lots and were tanned into both chrome and vegetable tanned leathers according to conventional methods.

Certain physical properties of chrome crust leathers were determined. Leather samples for physical testing were cut out carefully so that they retain maximum number of dermatitis lesions. Control samples were cut from the adjacent unaffected areas, SATRA grain crack values were determined by a lastometer and tensile strength, elongation, stitch tear resistance and tongue tear resistance were determined using Scott tensile strength tester.

Results

Histopathology

In sheep skin sections, the nodules appeared as mushroom shaped outgrowth above the skin surface. In some cases the edges of two separate outgrowths merged together leaving an empty space between the skin surface and the merged outgrowths. Two necrotised zones were noted, one of them, the outgrowth containing adnexa while the other was in the deep dermis and subcutaneous tissue. Besides proliferative and necrotic changes in the epidermis, the lesions showed severe inflammatory reactions with mononuclear and plasma cell infiltration in the dermis. Acanthosis and parakeratosis were also observed.

Hydrothermal stability of collagen fibres.

The T_S (average value of 30 fibres) of affected and unaffected collagen fibres was recorded to be 59° and 60°C respectively.

Observations on the dermatitis lesion during processing of the skins

Raw skin : Lesions on raw skin appeared as discrete circular nodules of 4 - 14 mm diameter and raised by about 1 - 2 mm above the grain surface (Fig. 1). Hair came out of the lesions easily with necrotic pellicle leaving eroded areas. The scab was firmly adhered to the underlying tissue. The nodules were found to be distributed throughout the skin but they were slightly more concentrated in the neck, tail root and legs. On the flesh side of raw skin, depressions were noted

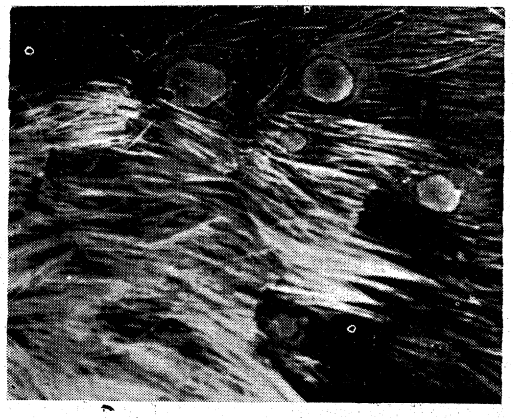

Fig. 1 : Appearance of dermatitis nodules on the hair side of raw sheep skin

corresponding to the nodules which, however, became prominent after fleshing. When viewed on a grading box, the lesions appeared as dark spots.

Limed pelt : After liming and unhairing, the lesions on the grain side appeared dark, well elevated and rubbery in consistency but some of them were pale in colour. They showed clear cut elevated margins on the grain. Removal of the scab during mechanical operations also resulted in considerable grain damage. A number of smaller lesions (2 mm and above) were found on the grain side without having corresponding depressions on the flesh side. White spots were noted on the flesh side corresponding to the nodules on the grain side.

Chrome crust : After tanning, the dermatitis lesions appeared as flat outgrowth on the grain side surrounded by channel like depressions around them (Fig 2). On the flesh side, round depressions were noted corresponding to the lesions. General appearance of the leathers became very poor due to (i) the presence of raised nodules throughout the leather and (ii) removal of the scab in many cases. Smaller lesions became prominent but had no effect on the flesh side. The lesions on the grain appeared slightly darker in shade but lighter on the flesh side. The lesion affected areas of leathers were also rough and stiff.

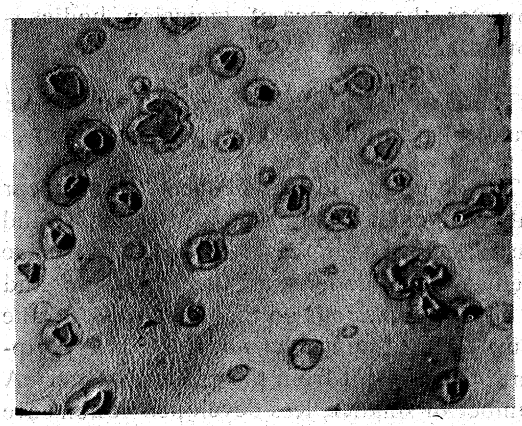

Fig. 2 : Appearance of sheep dermatitis nodules in chrome crust leather

Vegetable tanned leather : Lesions were clearly visible on both the grain and flesh sides of vegetable tanned leather. The raised nodules got flattened during setting operation but the margin of each lesion was clearly demarcated. As in case of chrome crust, the nodules were slightly darker on the grain and lighter on the flesh side. Circular depressions were noted on the flesh side corresponding to the nodules. The leather was hard and stiff in the affected areas.

Distribution of dermatitis nodules in sheep skin

The skins were demarcated into (1) neck and shoulder (2) lumbar and belly and (3) butt areas on each side to facilitate counting and the lesions were counted in raw skin, limed pelt and chrome crust leather. The results obtained are presented in Table 1.

Physical properties of the leathers

Physical properties of chrome tanned leathers, both from the affected and unaffected areas, were determined and the data obtained are presented in Tables 2 & 3.

In order to find out the effect of goat dermatitis on the quality of leather, a number of affected goat skins were collected and processed into leathers. It was apparent from a comparative study that dermatitis produced similar deteriorating effect on both sheep and goat skins as well as on leather produced from them and such affected skins were unsuitable for leather manufacture.

Discussion

Katiyar[5] was of opinion that the virus responsible for sheep dermatitis was different from viruses causing dermatitis in goat and

TABLE 1

Distribution of dermatitis lesions in different locations of sheep skins

Location	No. of lesions (average of 3 skins)					
	Raw skin		Limed pelt		Chrome crust	
	R	L	R	L	R	L
1. Neck & shoulder	42	43	120	115	119	114
2. Lumbar & belly	34	39	116	115	114	117
3. Butt	49	49	133	142	134	137
Total no. of lesions per skin (average)	256		741		735	

R = Right side;
L = Left side.

TABLE 2

Certain physical properties of chrome tanned sheep skins in the affected and unaffected areas.

	Unaffected	Affected
Tensile strength * (Kg/ cm thickness)	119.76	79.58
Elongation * (%)	81.7	50.0
Stitch tear resistance ° (Kg/ cm thickness)	78.39	56.43
Tongue tear resistance ° (Kg/ cm thickness)	12.40	10.29

*Average of 11 samples; ° Average of 6 samples.

contagious ecthyma and pox in sheep. It was later reported that[6] sheep dermatitis might actually be the manifestation of sheep pox with slight variance in the anatomicropathological changes. The virus responsible for goat dermatitis was recognised to be different[2] from that of goat pox but an examination of the nodules formed due to sheep and goat dermatitis revealed close resemblance in their appearance. In the present study, however, an attempt has been made to throw light on the leather making potentiality of sheep skin affected by dermatitis.

The histological characteristics of the dermatitis nodules in sheep skin are very similar to that reported by Katiyar[5] who observed that acanthosis and hyperkeratosis with occasional thickening of the dermis, cytoplasmic and intranuclear inclusions occurred in the lesion affected areas. In the present study, however, the presence of inclusion bodies is not noted.

The T_S of collagen fibres is found to be practically uninfluenced by sheep dermatitis.

The dermatitis lesions in sheep skin appear only in nodular form and not in vesicular and pustular form as in case of pox. They are seen as raised nodules on the hair side and as slight depressions on the flesh side of the skin. After liming, the nodules show peripheral detachment from the grain surface. A number of smaller, less developed lesions are exposed after unhairing which are not visible in the raw skins.

TABLE 3

SATRA grain crack values for chrome tanned sheep skins affected by dermatitis

Sample No.	*Unaffected*				*Affected*				*Grain crack resistance (Kg/cm. thickness)*		*Bursting resistance. (Kg/cm. thickness)*	
	Grain crack		*Bursting*		*Grain crack*		*Bursting*					
	D	*L*	*D*	*L*	*D*	*L*	*D*	*L*	*Unaffected*	*Affected*	*Unaffected*	*Affected*
1.	8.3	12	9.2	16	7.2	6	10.4	12	150.0	54 5	200.0	109.0
2.	8.6	12	10.3	18	6.6	4	9.2	12	150.0	40.0	225.0	109.0
3.	11.5	24	13.6	34	6.7	4	10.3	16	240.0	33.3	340.0	133.3
4.	10.5	18	11.4	20	6.8	4	9.7	14	200.6	40.0	222.0	127.2
5.	11.5	22	10.2	30	6.1	2	9.6	12	200.0	20.0	272.7	109.0
6.	8.9	30	10.1	32	6.0	2	9.0	8	428.5	13.3	457.1	53.3
7.	10.3	20	11.6	40	6.1	8	11.0	12	222.0	59.0	444.4	85.7
8.	8.7	10	9.0	28	5.8	4	9.4	12	142.8	40.0	400.0	109.0
9.	11.1	20	12.1	24	6.0	6	9.9	20	250.0	60.0	300.0	200.0
10.	8.1	8	9.6	18	7.0	8	11.5	20	142.8	57.1	257.1	142.8
Average	9.75	17.6	10.7	26	6.43	4.8	9.0	13.8	192.5	41.5	312.2	117.6

D = Distension in mm.
L = Load in Kg.

Grain crack distension value:
6.0 mm and below = sub-standard
7.0 mm = satisfactory
8.0 mm and above = very good.

After chrome or vegetable tanning, the lesions are clearly visible on both the grain and flesh sides and the general appearance of the leathers have become very poor.

Data presented in Table 1 indicate that the dermatitis lesions are distributed throughout the skin and leather though the lesions are slightly more in number in the butt region. The number of lesions in the limed pelt is found to increase significantly (189.45%) from that of raw skin, because of the fact that most of the developing lesions are not visible in the raw stage. Not much variation in count has been noted after tanning.

Tables 2 & 3 clearly indicate that the physical properties of the leathers are appreciably affected by dermatitis. Tensile strength, elongation and stitch tear strength values are lowered considerably and tongue tear resistance values slightly in the affected areas of leathers. The grain crack distension values in unaffected leathers are very good (average 9.75) but in affected leathers, most of the values are below satisfactory level. The grain crack load is also very low in affected leather. The bursting distension and load values of unaffected leathers are much higher compared to the corresponding values in affected leathers. Similarly the grain crack resistance and bursting resistance values of affected areas are found to be appreciably reduced due to the influence of dermatitis in skin.

It is apparent from the above investigations that dermatitis in sheep affects the general appearance as well as strength of the leather and renders it unsuitable for commercial exploitation.

Acknowledgement

The authors are thankful to the PL 480 authorities of the United States Department of Agriculture under whose grant this work was carried out. They are also thankful to Dr. N. Ramanathan, Acting Director, CLRI, for giving permission to publish the results.

REFERENCES

1. Bhambani, B. D. & Murthy., D. K., *J. Com. path.*, **73**, 249 (1963).

2. Haddow J. R. & Idnani, J. A., *Ind. Vet. J.* **26**, 332 (1948).

3. Green H. F., *J. Soc. Leather Trades chemist*, **40**, 259 (1956).

4. Green H. F., *J. Soc. Leather Trades Chemist*, **43**, 85 (1959).

5. Katiyar, R. D., *Ind. J. Vet. Sci.*, **31**, 132 (1961).

6. *Research in Animal Husbandry — A Review*, 1929 54 ICAR, 257, 1962.